

Neck Muscles in the Rhesus Monkey. I. Muscle Morphometry and Histochemistry

FRANCES J. R. RICHMOND,^{1,2,4} KAN SINGH,^{1,3} AND BRIAN D. CORNEIL^{1,2}

¹Medical Research Council Group in Sensory-Motor Neuroscience, ²Department of Physiology, and ³Department of Anatomy, Queen's University, Kingston, Ontario K7L 3N6, Canada; and ⁴School of Pharmacy, University of Southern California, Los Angeles, California 90033

Received 14 August 2000; accepted in final form 5 July 2001

Richmond, Frances J. R., Kan Singh, and Brian D. Corneil. Neck muscles in the rhesus monkey. I. Muscle morphometry and histochemistry. *J Neurophysiol* 86: 1717–1728, 2001. Morphometric methods were used to describe the musculotendinous lengths, fascicle lengths, pennation angles, and cross-sectional areas of neck muscles in adult *Macaca mulatta* monkeys. Additionally, muscles were frozen, sectioned, and stained for ATPase activity to determine fiber-type composition. Individual rhesus muscles were found to vary widely in their degree of similarity to feline and human muscles studied previously. Suboccipital muscles and muscles supplied by the spinal accessory nerve were most similar to human homologs, whereas most other muscles exhibited architectural specializations. Many neck muscles were architecturally complex, with multiple attachments and internal aponeuroses or tendinous inscriptions that affected the determination of their cross-sectional areas. All muscles were composed of a mixture of type I, IIa, and IIb fiber types the relative proportions of which varied. Typically, head-turning muscles had lower proportions of type II (fast) fibers than homologous feline muscles, whereas extensor muscles contained higher proportions of type II fibers. The physical and histochemical specializations described here are known to have a direct bearing on functional properties, such as force-developing capacity and fatigue-resistance. These specializations must be recognized if muscles are to be modeled accurately or studied electrophysiologically.

INTRODUCTION

Our understanding of human motor control often depends on extrapolating results from experimental animals. In the past, most studies of head movement have been conducted in cats. However, as more is learned about the skeletal relationships and musculature of the feline neck, differences are identified that may limit the usefulness of the cat as an appropriate model for human head movement. In a standing or sitting cat, the normal posture of the neck has a nearly right-angled flexure at the transition between the cervical and thoracic parts of the vertebral column (Vidal et al. 1986). The head and neck are cantilevered rostrally to the body so that gravitational forces on the head must be opposed by the actions of strong extensor muscles attaching to the thoracic vertebral column and shoulder girdle (MacPherson and Ye 1998; Runciman and Richmond 1997). In contrast, the human head is carried more directly over the trunk so that much of its weight is borne

passively on the pillar-like vertebral column (Graf et al. 1994, 1995a,b; Le Gros Clark 1962; Tobias 1992). The shoulder girdle in humans is also configured differently to facilitate the use of the arms and hands for object manipulation. For example, the clavicle is long and fixed, and the scapula is oriented in the frontal rather than the parasagittal plane. In parallel with skeletal changes, muscle attachments are reorganized and the number of extensor muscles is reduced (Kamibayashi and Richmond 1998; Oxnard 1967).

Monkeys may provide a better model than the cat for experimental studies of head movement. Monkeys are already used as the species of choice for many chronic studies of eye-movement control. Thus much is known about the organization and properties of neural circuits that are likely to participate in the control of at least one aspect of the “gaze”-control system coordinating head and eye movement (e.g., Cullen and Guitton 1997; Freedman and Sparks 1997; Moschovakis et al. 1996). Further, monkeys can be trained to carry out sophisticated movement sequences beyond the capabilities of even the most cooperative and highly motivated cat.

However, studies on monkey head movements have been impeded by a relatively poor foundation of information about musculoskeletal organization in the neck. A few anatomical surveys of neck muscles exist (e.g., Berringer et al. 1968; Hartman and Straus 1961; Szébenyi 1969), but the reports are qualitative and generally focus on superficial muscles. Further, almost nothing is known about the relative force-generating capacities and histochemical compositions of simian neck muscles even though such information can provide significant insights into their functional roles. These data must be acquired before neck muscles can be modeled or studied physiologically in any detail. Further, they would help to identify features that are dissimilar to those in humans. Some amount of dissimilarity should be expected because rhesus monkeys are terrestrial quadrupeds, although they can resort to facultative bipedalism when required (Juschke 1972; Napier and Napier 1985) with narrower shoulder girdles and scapulae that are oriented more parasagittally than those of human primates (Le Gros Clark 1962; Oxnard 1967).

In present studies, we have evaluated the morphometry and fiber-type distribution of neck muscles in the rhesus monkey.

Present address and address for reprint requests: B. D. Corneil, Div. of Biology, California Institute of Technology, MC 216-76, Pasadena, CA 91125 (E-mail: brian@vis.caltech.edu).

The costs of publication of this article were defrayed in part by the payment of page charges. The article must therefore be hereby marked “advertisement” in accordance with 18 U.S.C. Section 1734 solely to indicate this fact.

Methods were chosen to complement a similar recently published analysis of human neck muscles (Kamibayashi and Richmond 1998). Data from the present work identify a number of differences in muscle structure between these two primates and serve as a basis for biomechanical models of the rhesus head-neck system. They further provided an anatomical guide for functional studies of neck muscles reported in the companion paper (Corneil et al. 2001).

METHODS

Systematic morphometric measurements of neck muscles were made in three adult female rhesus monkeys *Macaca mulatta* (7.4–7.9 kg) and supplemented by further measurements on selected muscles in an additional four animals (2 female, 5.3–6 kg; 2 male, 5.7–6.3 kg). Histochemical analyses were carried out on neck muscles removed from six rhesus monkeys (4 female, 4.7–5.7 kg, and 2 male, 6.2 and 7.5 kg). The monkeys were housed in a light- and temperature-controlled environment. All animal-care and experimental procedures were carried out according to the guidelines of the Canadian Council on Animal Care and were approved by the Queen's University Animal Use committee. Some monkeys had previously been subjects in electrophysiological studies of the superior colliculus or in studies of reproductive hormone cycling that did not appear to affect the musculature. The animals were anesthetized intravenously with a mixture of Saffan (alphaloxalone and alphadolone acetate, Cooper's Agrofarm, Ajax, 0.5 ml/kg) and ketamine hydrochloride (Rogar/STB, 6–9 mg/kg iv). In some monkeys, the carotid arteries were catheterized, and the brains of the monkeys were perfused, first with phosphate-buffered saline and then with 4% paraformaldehyde solution. The other monkeys were killed with an overdose of pentobarbital sodium.

Morphometry

The muscles under investigation were weighed and fixed in 10% formalin. Fixed muscles were reweighed. Fascicle lengths were measured at different sites across the muscle width on both the superficial and deep surfaces of the muscles. In muscles in which fascicle length changed progressively across the width or depth of the muscle, the muscle was modeled as one or more parallelograms and mean fascicle length was computed by averaging the lengths of fascicles composing the long and short sides. Cross-sectional areas of simian muscles were also scaled up or down to facilitate comparisons with homologous muscles in humans and cats by relating an 8-kg monkey to a 64-kg human or a 3.35-kg cat. If the musculature of the three species was to be similar geometrically, the linear dimensions from cat to monkey to man should scale in a ratio of 1.5:2:4 and cross-sectional areas (CSAs) should scale in a ratio of 2.25:4:16 (linear dimension²) (Schmidt-Nielsen 1984). Pennation angles (θ) were measured with respect to the line-of-pull of the muscle using a protractor. Physiological CSAs (PCSA) were calculated using the equation, $PCSA = \text{mass (g)} \times \cos \theta / \text{fascicle length (cm)} \times \text{density (g/cm}^3\text{)}$. A uniform density of 1.06 g/cm³ was assumed (Mendez and Keys 1960). Sarcomere lengths were measured by examining the fibers of small excised pieces of muscle from at least three different sites using 100 × oil immersion objective as described in detail elsewhere (Selbie et al. 1993). Fascicle lengths from the sampled muscle were then normalized by adjusting the value of length to that appropriate for a standard sarcomere length of 2.5 μm (Herzog et al. 1992).

Histochemistry

Muscles were dissected for histochemical analysis within 3 h after the death of the animal. They were divided into blocks 1–2 cm in height that were mounted using embedding medium in a recorded orientation onto numbered cryostat chucks. The blocks were covered

with talcum powder and immersed in liquid nitrogen where they were stored. Sets of serial 16-μm sections were cut using a cryostat and mounted on gelatin-coated slides. Sequential sections were stained with hematoxylin and eosin and for myosin adenosine triphosphatase (ATPase) activity after alkaline preincubation at pH 10.4 (Guth and Samaha 1970). Sections to be stained for ATPase activity were kept in a sealed container containing a desiccating compound for ≤2 h after being cut to minimize hydration of tissue and loss of enzyme reactivity. Systematic variation of staining variables for ATPase staining showed that consistent differences between fiber types were obtained by fixing sections in 5% formalin for 2.5 min rather than 5 min and preincubating them in alkali solution for 4 min rather than 15 min. Sections were immersed in 1% ammonium sulfide for 1 min rather than the 3 min recommended in original protocols.

Stained sections were magnified and drawn with the aid of a microfiche reader. Some sections were scanned using a high-resolution color scanner or slide scanner adapted for histological sections (SprintScan 35 Plus, Polaroid). Regions containing obviously different fiber-type proportions were identified. At higher magnification, fibers were classified as type I (equivalent to SO; light staining), type IIa (FOG; intermediate staining), and type IIb (FG; dark staining) types by criteria described previously (Bagnall et al. 1983; McIntosh et al. 1985) (Fig. 1). Relative contents of different fiber types were estimated by identifying the staining profiles of ~200 fibers at three to five sites in each cross-section (Richmond and Abrahams 1975).

RESULTS

Muscles invest the monkey neck in several layers. The largest and most superficial layer is composed of muscles that link the skull and cervical vertebrae to the shoulder girdle. Intermediate layers consist chiefly of long muscles linking the skull to lower cervical and thoracic vertebrae. The deepest muscles connect the skull to upper cervical vertebrae, or interconnect vertebral bones.

Muscles that link the head and neck with the shoulder girdle

TRAPEZIUS. *Trapezius* (TRAP) is a broad, sheet-like muscle that originates from occipital crest of the skull and the vertebral midline between the skull and T₁₀ (Fig. 2; see Table 1 for a list of muscle abbreviations). At both ends of its vertebral origin, fibers attach directly to the midline raphe, but in the upper thoracic region, the muscle attaches to the midline by way of a diamond-shaped aponeurotic sheet. Fascicles run caudolaterally to attach in a continuous line onto the distal margin of the clavicle, the acromion, and the scapular spine. At the caudal-most end of the scapular spine, fibers from thoracic vertebrae converge to form a semilunar array radiating from a short, thick tendon that focuses much of the force-generating capacity of the caudal muscle on a narrow site (Fig. 2).

Fascicle lengths in TRAP vary widely, from 7 cm at the rostral margin to ~2 cm in the shortest region at about the level of the scapular spine (Table 1). For purposes of morphometric analysis, the muscle was divided into three parts comparable in fiber direction (but not insertions on the clavicle and scapula) to divisions used elsewhere to analyze human and feline TRAP (Kamibayashi and Richmond 1998; Richmond et al. 1999a). The largest, rostral part that attached to the clavicle and spine of the scapula had the largest CSA (≥2 cm²; Table 1). The remaining parts, composed of horizontal and descending fascicles, together had CSAs of only 1.5–2 cm².

TRAP had a nonuniform distribution of fiber types that was suggested from visual inspection by the lighter color of the rostral




FIG. 1. Identification of rhesus fiber types according to ATPase reactivity. Note that adjacent fascicles of fibers have strikingly different proportions of fiber types, even in regions in which overall proportions are similar. Bar = 100 μm .

part of the muscle. Analysis of ATPase-stained sections showed that rostral TRAP was composed predominantly of type IIb fibers (Table 2). At the transition from upper to middle TRAP, the proportion of type I fibers increased markedly and typically became the predominant fiber type in middle and lower TRAP. In some muscles, slow fiber proportions were somewhat higher in the muscle core than the superficial surface.

STERNOCLEIDOMASTOID. *Sternocleidomastoid* (SCM) is a superficial muscle whose three strap-like heads wrap around the lateral neck in a pattern like that in man (Kamibayashi and Richmond 1998) (Fig. 3). The most medial head, *sternomastoid* (SM), originates on the manubrium and inserts at a pinnation angle of 10–20° onto a thickened tendon attaching to the mastoid process. Two muscle heads with clavicular insertions are located lateral and deep, respectively, to SM. The *cleidooccipital* (CO) head has a similar length and CSA to SM

($\sim 0.5 \text{ cm}^2$, Table 1), but is wider and thinner. It originates from on the medial part of the clavicle. As it runs rostrally, it fuses to the lateral edge of SM and extends its attachment onto the occiput adjacent to the mastoid process. The third head, *cleidomastoid* (CM), has a relatively small CSA ($\sim 0.3 \text{ cm}^2$). It originates deep and medial to CO, crosses obliquely on the undersurface of SM and inserts deep to it on the mastoid process. CM is mostly, or entirely, hidden when the muscle is viewed from the superficial surface (Fig. 3).

SCM is composed primarily of fast fiber subtypes. Fast fibers account for 90% or more of fibers on the superficial surface and lateral edges of most specimens. Type I fibers are distributed more densely (20–50% of fibers) in the middle part of the muscle where CO and SM abut.

RHOMBOIDEUS. *Rhomboides* (RH), like trapezius, has a broad origin from the skull and nuchal midline raphe. In most spec-

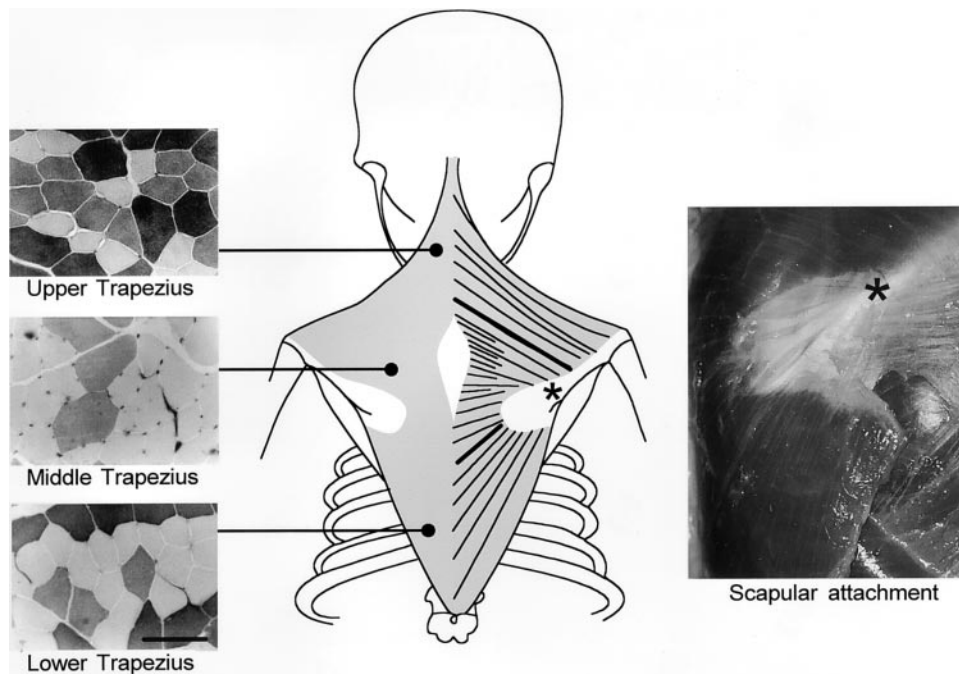


FIG. 2. Anatomy and histochemistry of trapezius. The analysis of trapezius is complicated by the heterogeneity of fiber lengths. To simplify description, the muscle was divided into 3 parts along the thick lines in the muscle drawing. *Left:* upper trapezius was relatively rich in type IIb fibers, which stain darkly for alkali-stable ATPase activity, whereas moderately staining type IIa and lightly staining type I fibers were more common caudally. Bar = 100 μm . *Right:* middle and lower trapezius converge onto a radially organized tendon (*) attaching to the scapular spine.

TABLE 1. *Morphometric parameters of rhesus neck muscles*

Muscle	Abbreviation	<i>n</i>	Mean Mass, g	Mass Range, g	FL Mean, cm	θ°	NORM FL, cm	PCSA, cm ²	PCSA Range, cm ²
Trapezius	TRAP								
Upper	uTRAP	4	13.1	9.8–14.9	5.0 (1.5–9)	—	5.3	2.38	1.99–3.14
Middle	mTRAP	4	1.6	1.2–1.8	2.3 (1.2–3.6)	—	2.6	0.61	0.42–0.94
Lower	lTRAP	4	5.1	3.5–6.5	4.7 (1.9–7.3)	—	5.1	0.94	0.63–1.14
Sternocleidomastoid	SCM								
Sternomastoid	SM	3	3.4	3.2–3.8	6.5 (5.0–7.5)	10	6.6	0.49	0.43–0.60
Cleidomastoid	CM	3	2.1	2.1–2.2	6.7 (6.0–7.5)	10	6.5	0.31	0.28–0.36
Cleidococcipital	CO	3	3.4	3.0–3.6	7.2 (6.4–8.5)	—	6.7	0.48	0.41–0.58
Rhomboideus	RH								
Capitis	RH cap	3	1.3	1.1–1.6	6.3 (5.0–7.2)	—	6.6	0.19	0.14–0.24
Cervicis	RH cerv	3	6.3	5.4–6.9	4.1 (2.8–8.1)**	—	5.9	1.00	0.96–1.04
Dorsi	RH dorsi	3	4.1	3.0–5.9	3.5 (3.2–3.9)	—	4.4	0.88	0.66–1.24
Atlantoscaphularis									
Atlantoscaphularis anterior	AS ant	4	4.3	3.3–4.9	5.5 (4.0–6.2)	—	6.3	0.65	0.49–0.78
Atlantoscaphularis posterior	AS post	3	7.0	4.1–9.2	5.6 (3.5–7.0)	—	6.7	1.03	0.55–1.43
Splenius									
Splenius capitis	SP cap	3	7.1	6.5–7.8	4.5 (1.7–7.2)	—	4.2	1.59	1.50–1.72
Longissimus									
Longissimus capitis	LONG cap	3	1.9	1.7–2.3	4.5 (1.8–6.6)	—	4.8	0.38	0.35–0.43
Longissimus dorsi (including serratus)	LONG dorsi	2	19.8	17.2–22.4	3.9 (1.7–6.1)	—	4.8	3.89	3.56–4.23
Semispinalis capitis	SS cap								
Biventer cervicis	BC	3	3.7	3.3–3.9	6.9 (6.3–9.0)	—	7.6	0.44	0.42–0.46
Complexus	COM	3	4.0	3.1–4.9	4.1 (2.5–6.0)	—	4.1	0.93	0.68–1.09
Suboccipital Muscles									
Rectus capitis posterior major	RCP maj	4	0.9	0.7–1.1	1.6 (1.0–2.1)	—	1.7	0.49	0.46–0.57
Rectus capitis posterior minor	RCP min	3	0.6	0.5–0.7	1.1 (0.5–1.6)	5	1.1	0.53	0.45–0.56
Obliquus capitis inferior	OCI	5	0.6	0.5–0.7	1.6 (1.2–2.2)	—	1.5	0.37	0.24–0.48
Obliquus capitis superior	OCS	3	0.7	0.6–1.0	1.3 (0.7–1.9)	15	1.4	0.47	0.37–0.66
Rectus capitis anterior major	RCA maj	3	1.0	0.7–1.1	2.1 (0.8–3.0)	—	2.5	0.39	0.26–0.57
Intervertebral Muscles									
Semispinalis cervicis	SSC	3	2.3	1.2–3.5	2.4 (0.9–4.4)	—	2.6	0.90	0.41–1.55
Scalenus									
Scalenus posterior	SCA post	3	5.7	4.9–7.2	5.1 (1.7–9.0)	—	5.5	1.02	0.72–1.31

Data for each muscle or muscle head represent mean values for that variable from at least 3 animals. For each animal, sarcomere lengths, normalized fascicle lengths, and cross-sectional areas (CSAs) were computed separately. Thus the mean CSA represents the average of 3 or more individual values and will not necessarily correspond to a value obtained by using "mean" weights and normalized fascicle lengths. Parentheses enclose ranges. PCSA, physiological CSA.

imens, its rostral part appeared as a thin ($CSA = 0.1\text{--}0.2\text{ cm}^2$), separate, strap-like head called *rhomboides capitis* (RH cap) that ran between the medial part of the occipital crest and the vertebral border of the scapula (Fig. 4). In a few animals, the muscle origin also lapped from the skull onto the nuchal midline raphe. In a single case, this origin was particularly wide and the lateral edge of the muscle was fused to the adjacent rhomboides cervicis.

The main body of rhomboides is composed typically of two conjoined parts, *rhomboides cervicis* (RH cerv) and *rhomboides dorsi* (RH dorsi). The heads originate sequentially from the vertebral midline and insert along the vertebral border of the scapula (Fig. 4). At vertebral origin, fascicles attach to a short, thickened aponeurosis that is more obvious on the deep muscle surface. Correspondingly, the fiber fascicles on the deep surface are typically a few mm shorter than those on the superficial surface. The boundary between the two heads is placed by convention at the midpoint of the scapular spine (Hartman and Straus 1961), but this line of division can be difficult to discriminate. When muscle heads are separated at this point of division, the two parts have similar CSAs (Table 1).

Fiber-type distribution in RH was nonuniform. RH cap was relatively rich in type I fibers ($\sim 40\text{--}50\%$; Table 2). The proportion of type I fibers diminished progressively from the

rostral to caudal end of RH cerv and that of type IIb fibers increased correspondingly (e.g., $\sim 30\%$ type IIb fibers rostrally vs. 50% caudally). In RH dorsi, type II fiber proportions continued to increase from the rostral to caudal end of the muscle.

ATLANTOSCAPHULARIS. The scapula is linked to the cervical vertebral column by two atlantoscaphularis muscles. *Atlantoscaphularis anterior* (AS ant) is homologous to levator scapulae ventralis in cats and humans (e.g., Kamibayashi and Richmond 1998; Richmond et al. 1999a). It is a thick strap lying immediately deep to trapezius that attaches to the lateral (coracoid) half of the scapular spine (Fig. 4). It runs rostrally for $\sim 5\text{ cm}$ and inserts on the ventral border of the transverse process of C_1 .

Atlantoscaphularis posterior (AS post) attaches along the proximal one-third of the vertebral border of the scapula close to the site of attachment of RH cap and runs cranially to insert onto the dorsal surface of the C_1 transverse process (Fig. 4). AS post has been described as a distinct muscle that is separate from a large adjacent muscle sheet, serratus anterior, that attaches to the rest of the cervical vertebrae (Fig. 5) (Hartman and Straus 1961). However, the point of division is marked only by a small gap close to the rostral muscle end, and the features of the subvolume are similar to those of the subvolumes of serratus attaching to more

TABLE 2. Fiber-type proportions in rhesus neck muscles

	I Ib	I Ia	I I
Trapezius			
uTRAP	53	21	26
mTRAP	24	31	45
ITRAP	28	27	45
Sternocleidomastoid			
SM	42	35	23
CO	40	32	28
Rhomboideus			
RH cap	32	23	45
RH cerv	35	25	40
RH dorsi	47	30	23
Atlantoscapularis			
AS ant	32	24	44
AS post	49	22	29
Splenius			
SP cap	39	24	37
Longissimus			
LONG cap	37	30	33
LONG dorsi	34	21	45
Semispinalis			
BC	32	28	40
COM	41	29	30
Intervertebral			
Muscles			
SSC & SD	33	29	38
Scalenus			
SCA post	33	40	29

The proportions of the different fiber types is shown for various muscles or muscle heads. The data represent the percentages averaged over several sites collected in each of several monkeys.

caudal vertebrae. In other species, AS post and the conjoined cervical part of serratus anterior are considered together as a single muscle called levator scapulae dorsi as shown in Fig. 6A (e.g., cat: Reighard and Jennings 1963; human: Kamibayashi and Richmond 1998).

Both AS post and AS ant were composed primarily of fast fiber subtypes (Table 2) although AS post had somewhat higher contents of type IIb fibers. In AS ant, a widely varying pattern of fiber-type distribution gave the muscle cross-sections a patchy appearance under low-power magnification. Higher proportions of type IIb fibers were present on surface (35–65%) than core regions (5–35%). In AS post, higher proportions of type IIb fibers were found on the medial aspect of the muscle, and this was reflected in a paler visual appearance of the medial muscle in several specimens.

SCALENUS. Scalenus is a laterally placed set of muscle heads whose complex relationships and attachments between vertebrae and the scapulae and ribs have been described and illustrated in detail previously for *M. cyclopis* (Hsiao 1976). Only the most cervical of the heads, *scalenus brevis posterior* (SCA post), was studied quantitatively. It originates on a narrow site dorsolaterally on the first rib and attaches to the transverse processes of vertebrae of C₁–C₇ (although in 1 animal the attachment to C₁ was absent). Scalenus has an unusually high content of type IIa fibers (35–50%, Table 2) and more modest densities of type IIb (15–40%) and I (20–35%) fibers. Type I fibers tend to be most dense in the core of the muscle.

Muscles linking the skull and vertebral column

SPLenius. *Splenius capitis* (SP cap) is a large muscle (CSA \cong 1.5 cm², Table 1) that originates from the nuchal midline as far

caudally as T₃ or T₄ and runs rostralaterally to insert along the whole width of the occipital crest (Fig. 7A). A narrow lateral strip that inserts on the lateral wing of the atlas called *splenius cervicis* (SP cerv) can also be recognized in some animals (Fig. 6C). Like feline splenius (Richmond et al. 1985), rhesus SP cap is crossed laterally by two inscriptions that do not span the whole width of the muscle (Fig. 7A).

SP cap is composed of ~40% type I fibers that are distributed in somewhat higher densities medially than laterally. In two of three monkeys, one or more fascicles were found in which only type I fibers were present, and these were interposed between more typical fascicles in which type I fibers accounted for only 30–50% of fibers.

LONGISSIMUS. Three parts of longissimus can be identified in the cervical region. Lateral to SP, *longissimus capitis* (LONG cap) originates from the transverse processes of upper thoracic and lower cervical vertebrae and inserts onto a tough narrow tendon close to the mastoid process (Fig. 6C and 7B). At its caudal limit it appears to merge with the attachments of biventer cervicis. LONG cap has at least one inscription through its midsection. It contains a relatively even mix of type IIb, IIa, and I fibers. *Longissimus cervicis* (LONG cerv) lies on the lateral aspect of LONG cap (Hartman and Straus 1961). It is composed of shorter fascicles spanning between the tubercular processes of thoracic vertebrae and the transverse processes of cervical vertebrae (Fig. 6C). The complex relationships and relatively small size of this component made analysis difficult and morphometric measurements are not included in Table 1.

Superficial



Deep

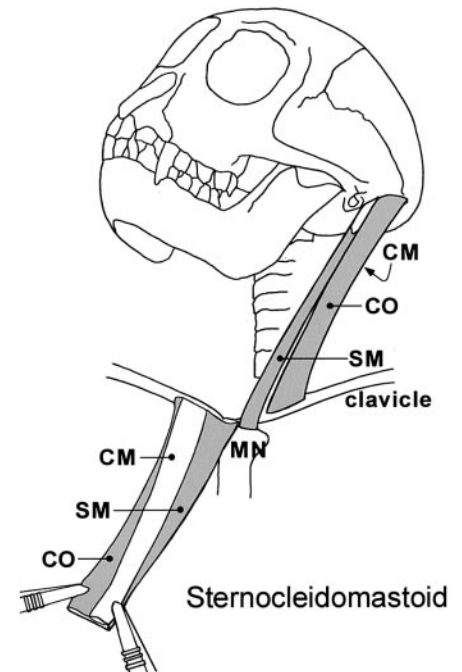



FIG. 3. Organization of muscle heads in sternocleidomastoid. From the superficial surface, the muscle appears to be a parallel-fibered sheet that can be divided for purposes of analysis into 2 heads (SM and CO), shown schematically in the line drawing (right). On the deep surface, a 3rd head (CM) can be recognized by its oblique orientation relative to overlying muscle. The boundaries of this deep head are shown more clearly in the companion line drawing. MN, manubrium.

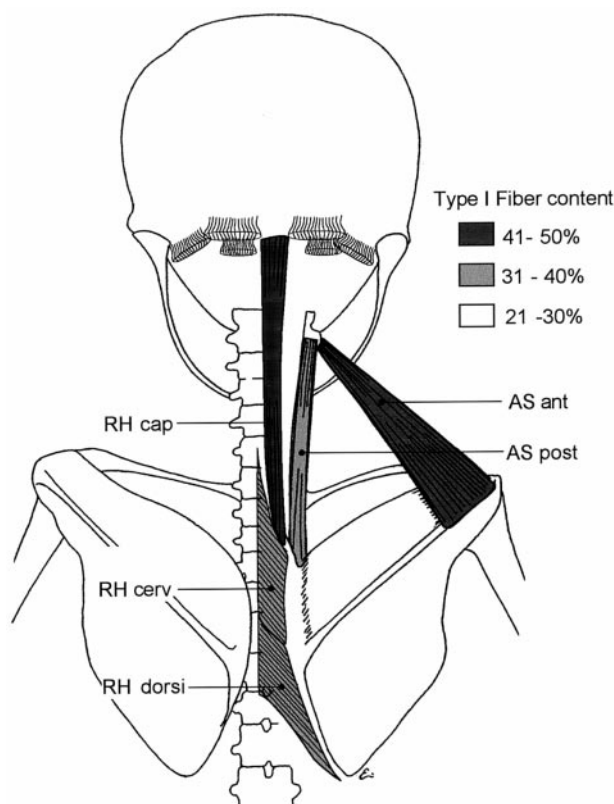


FIG. 4. Schematic drawing to illustrate attachments of rhomboideus and atlantoscapularis muscles. The intensity of shading reflects the relative proportion of type I fibers in each muscle head. In this posture, the vertebral borders of the scapulae are positioned close to the vertebral column so that fascicles composing RH cerv and RH dors are very short. When the animal adopts a quadrupedal posture, the scapula is more parasagittal and the muscles are longer. Abbreviations as in Table 1.

A third component of longissimus, called *longissimus dorsi* (LONG dors), also extends into the neck (Hartman and Straus 1961; but see Szebenyi 1969 for an alternate definition of longissimus cervicis). It is a fleshy muscle that originates from the lumbodorsal fascia and runs laterally to insert onto thoracolumbar vertebrae, ribs, and the transverse processes of cervical vertebrae caudal to C_2 . For present analyses, the cervical portion of this very large muscle was isolated arbitrarily by making a cut in parallel with the long axis of the muscle fibers along a line originating at the C_7 - T_1 junction. LONG dors is richer in type I fibers and poorer in type IIa fibers than LONG cap (Table 2), but contents of type IIb fibers are similar in the two muscles.

SEMISPINALIS CAPITIS. *Semispinalis capitis* (SS cap) lies deep to splenius. It has two parts, called *biventer cervicis* (BC) and *complexus* (COM) (Hartman and Straus 1961) that are partially fused in most animals but separated in a few specimens (Fig. 7B). The more medial BC is a parallel-fibered muscle that originates from tendinous strands attaching to the ribs and tubercular processes of thoracic vertebrae T_3 - T_7 . It inserts medially on the occipital crest. The architecture of the muscle is made complex by the presence of two to three tendinous bands or strips that vary in prominence from one animal to another (Fig. 7B). Immediately lateral on the occipital crest is the attachment of COM. Its fibers arise as a series of slips from the tubercular processes of the most rostral two or three tho-

racic vertebrae and from transverse processes of vertebrae C_3 - C_7 . These slips insert onto an inscription that crosses the width of the muscle. From the other side of the inscription arise fibers that run rostrally to the occiput.

BC and COM contain a relatively even mix of fiber types, although BC typically has ~10% more type I fibers and 10% fewer type IIb fibers than COM (Table 2). The medial edge of COM typically contains more type I fibers (>35%) than the lateral edge (<25%).

SUBOCCIPITAL MUSCLES. The upper cervical vertebrae are invested with short muscles that cover all surfaces of the axis and atlas. Dorsally are two muscle groups, the rectus capitis posterior group and the obliquus capitis group (Fig. 7C). *Rectus capitis posterior* (RCP) has two fan-shaped layers that have similar CSAs. The most superficial layer is formed by *rectus capitis posterior major* (RCP maj), which arises below the lateral part of the occipital crest (Fig. 7C). It runs at an angle of ~25° with respect to the longitudinal midline and converges to a narrowed attachment on the spinous process of C_2 . Deep and medial to it is *rectus capitis posterior minor* (RCP min), which runs from the medial occiput to the dorsal arch of the axis. It is shorter and lighter than RCP maj, and can be difficult to remove without damage. *Obliquus capitis inferior* (OCI) is a fleshy short strap that runs obliquely from the spinous process of C_2 to the transverse process of the atlas (Fig. 7C). *Obliquus capitis superior* (OCS) runs from the rostral aspect of the C_1 transverse process to the lateral part of the occiput, deep and lateral to RCP maj. It has a pinnate organization around a buried aponeurosis so that its fascicle lengths are shorter and CSA is larger than might be predicted by modeling the muscle as a simple strap.

Both rectus and obliquus muscles were found to have a markedly nonuniform distribution of fiber types despite their small size, so that it is risky to assign a single value for fiber-type proportions (Table 3). RCP maj and min had a steep gradient in the distribution of fiber types in which type II fibers predominated on the dorsal surface whereas type I fibers predominated deeper. OCI had a particularly nonuniform organization. The deep surface of the muscle was composed exclusively or almost exclusively of type I fibers whereas the dorsal surface was composed almost entirely of type II fibers, as described in more detail elsewhere (Richmond et al. 1999b). Only in OCS was it typical to find differences of <20% in the proportions of any one fiber type from one muscle surface to the other.

On the lateral aspect of the neck is a single muscle, *rectus lateralis* (RCL), that runs from the transverse process of C_1 to the lateral occiput alongside OCS. Ventrally, *rectus capitis anterior minor* (RCA min) originates from the ventral surface of C_1 and runs for a short distance rostrally to the basi-occiput deep to the attachment of longus capitis. These small muscles are very difficult to dissect and preserve without damage so that measurements could not be made with accuracy. From measures made in a single animal, the CSAs of RCL and RCA min were estimated to be <0.3 and 0.1 cm², respectively. RCL in an analyzed single specimen had a fiber-type ratio averaging 25% IIb/35% IIa/40% I fibers while RCA min was composed of 50% IIb/35% IIa/15% I fibers.

An additional muscle that is often considered as part of the rectus capitis grouping is not strictly confined to the upper

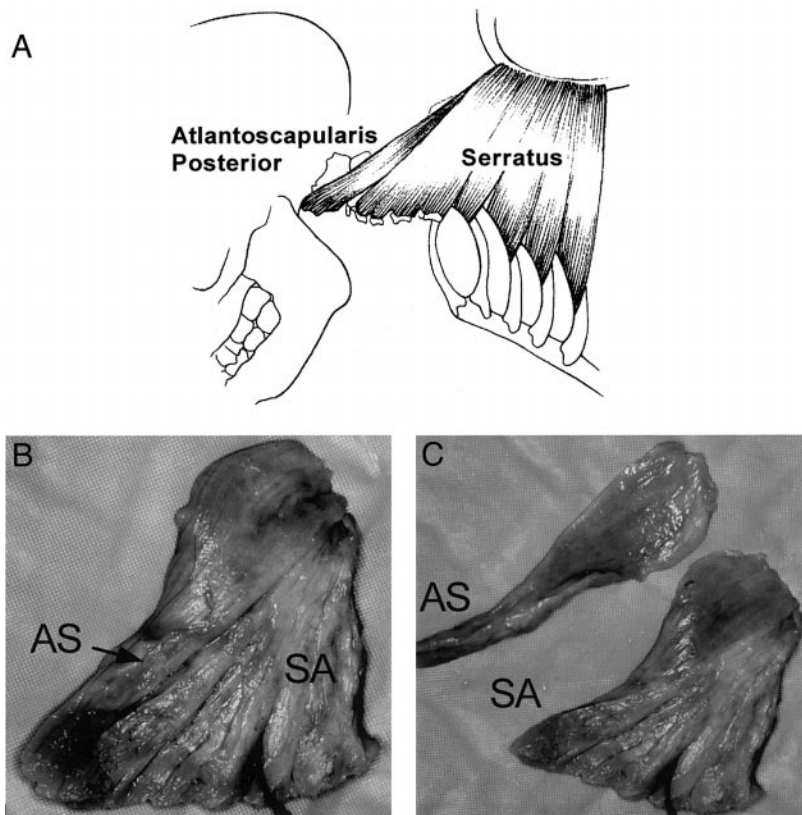


FIG. 5. Differentiation of AS post from serratus anterior (SA). A: schematic drawing shows the dorsal surfaces of AS post and serratus anterior. AS post attaches to C_1 , whereas serratus anterior attaches to the transverse processes of cervical vertebrae and to ribs. See Fig. 6A for alternate nomenclature describing the same complex. C: photographs of ventral surface of conjoint AT and rostral serratus anterior (SA). In B, the AS post is fused to the remaining "serratus." In C, the part considered to be AS post has been peeled away from the laminated composite muscle. However, similar slips attaching to more caudal vertebrae can also be peeled away sequentially, suggesting that this muscle is composed of a series of individual subvolumes.

cervical region. *Rectus capitis anterior major* [RCA maj, also called longus colli (Hartman and Straus 1961)] runs from the transverse processes of C_2 – C_6 and inserts on the base of the skull adjacent to the site of attachment of RCA min (Fig. 6B). The muscle has a specialized architecture with two heads. The short medial head has fine buried aponeuroses, whereas the long head has a prominent superficial aponeurosis that laps over the vertebral attachments of the short head in a pattern reminiscent of that described and illustrated previously in cat (Selbie et al. 1993) and man (Kamibayashi and Richmond 1998). The medial head tends to contain a more uniform distribution of fibers (Table 2). In the long head, groups of fascicles have strikingly variable fiber-type proportions around a buried aponeurosis, and in one animal a large fascicle was found to contain all type I fibers. Thus it is difficult to assign a "typical" fiber-type ratio to RCA maj.

Intervertebral muscles

Several small muscles invest cervical vertebrae caudal to C_2 . Only limited sampling and observations of these deeply placed muscles were possible because they were difficult to remove without damage. *Spinalis dorsi* (SD) and *semispinalis cervicis* (SSC) lie dorsally and dorsolaterally, deep to *semispinalis capitis* (Fig. 7C). SD is relatively small and joins successive spinous processes of cervical vertebrae. It appears to fuse with SSC that joins the spinous processes of the same vertebrae with transverse processes of vertebrae located more caudally. Fascicles in the lateral part of the muscle are shorter and attach to more caudal cervical vertebrae than those in the medial part of the muscle. Medial fascicles also have a less angled orientation with respect to the vertebral midline. In two muscles, fascicles

in most regions contained a relatively even overall mix of fiber types (Table 2), although some central fascicles contained 40–50% type I fibers.

Multifidus muscles are intertransverse muscle slips that invest the lateral aspects of the vertebrae, lateral to *semispinalis cervicis*. Fiber bundles link transverse processes, one, two, or three vertebrae away from their origins. These muscles were not sampled.

The ventral aspects of the vertebrae are invested by the muscle *longus colli*. This muscle is also complex. It is composed of fiber bundles that form pinnate slips joining the ventral surfaces of the cervical vertebrae to the transverse processes of more caudal counterparts. This complex architecture made morphometric analysis very difficult so that values of CSA could not be estimated reliably without more sophisticated microdissections beyond the scope of this analysis. In the one muscle that was examined histochemically, type I fiber proportions were low (~25%) and type IIb and IIa fibers accounted for 40 and 35% of fibers, respectively.

DISCUSSION

Studies of rhesus neck muscles afford an opportunity to examine the comparative anatomy of a species that appears to be transitional in its neck-muscle organization between human bipeds and nonprimate quadrupeds such as cats (see also Graf et al. 1994). At least two differences from previously studied quadrupeds may be particularly significant functionally. First is the relative reduction in the size and numbers of the available extensor muscles. Second is the differing arrangement of shoulder-girdle muscles around the fixed clavicle and scapula. The differences in shoulder-girdle attachments change the lines

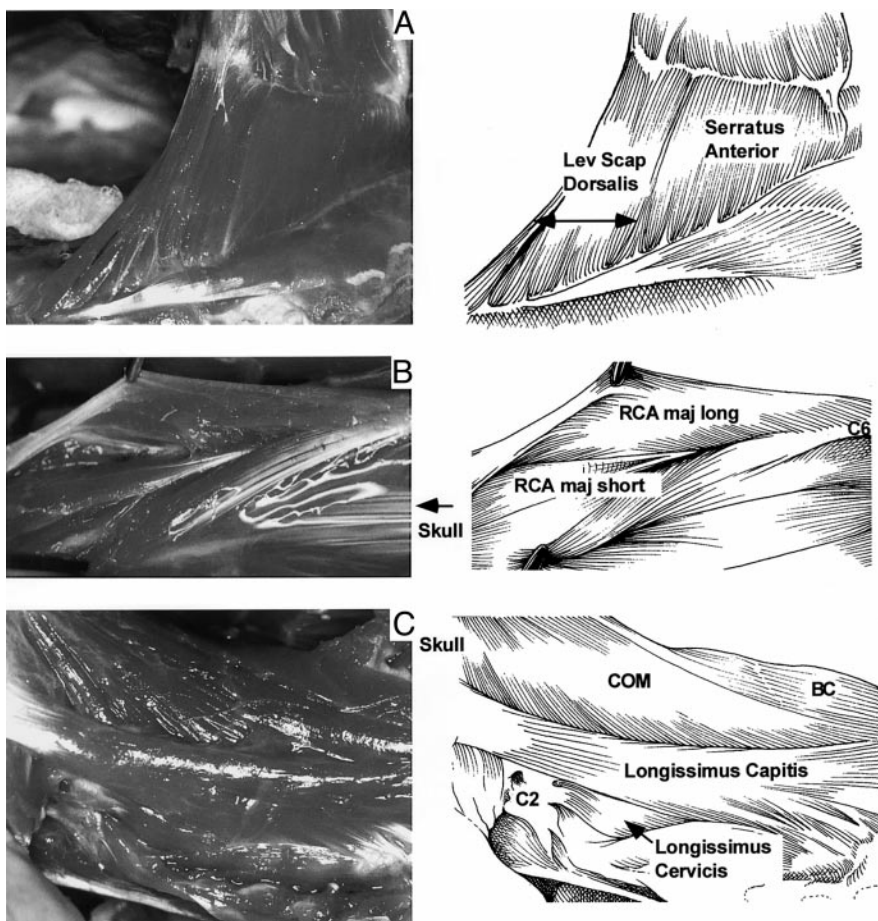


FIG. 6. Anatomical relationships of 3 complex neck muscles. *A*: differentiation of levator scapulae dorsalis and serratus anterior according to alternate nomenclature like that in feline literature. Note that the muscles are the same as those in Fig. 5, but the point of division is identified differently. *B*: rectus capitis anterior major (RCA maj). The short head is located alongside the long head, which is reflected. *C*: longissimus capitis and cervicis. Both muscles run on the lateral margin of the cervical column. Note the larger size and stout tendon of longissimus capitis. The attachment of complexus (COM) is also visible above the dorsal edge of longissimus capitis.

of pull of some muscles. These muscles also exhibit differences in CSAs and fiber-type distributions when compared with those of quadrupeds, presumably reflecting specializations in functional roles.

Differences in dorsal extensors

In both cats and monkeys, dorsal neck muscles are larger and more numerous than ventral muscles. A strong set of dorsal muscles is needed presumably to hold up a heavy head whose center of mass is located in front of the vertebral column (Tobias 1992). In cats, the forward movement of the head is known to be opposed by tonic contractions in at least two dorsal muscles, occipitoscapularis (equivalent to RH cap) and BC (Richmond et al. 1992) that are rich on type 1, or slow, fibers (Richmond and Abrahams 1975). In rhesus monkeys, homologous muscles were found to have somewhat lower type I fiber proportions than feline muscles (Fig. 8). The lower content of slow fibers did not appear to be due to an “across-the-board” decrease in type I fiber contents in rhesus muscles; other muscles in the rhesus neck had higher type I fiber contents than homologous feline muscles (Fig. 8). The relative CSAs of rhesus extensors also differed from values that might be expected if the CSAs of homologous feline muscles were simply scaled up (Fig. 9). The CSA of RH cap in the monkey was found to be ~2.5 times that of feline occipitoscapularis (rather bigger than might be expected from scaling increases alone), whereas those of BC and COM were smaller than might be expected. The overall diminution in CSA may reflect the

fact that the center of mass for the monkey skull is closer to the vertebral column (Tobias 1992), so that relatively smaller forces should be needed to counteract gravitational torques at the skull-C₁ joint. Nevertheless, biomechanical analyses will be needed to identify whether these differences, which will affect force-developing capacity, are offset by moment-arm changes due to differences in the skeletal geometry and muscular sites of attachment.

The dorsal extensor muscles studied here contained a mix of anatomical elements that could be related in some instances to forms described in cats but in others to the quite distinct morphology of human muscles. For example, “semispinalis capitis” was found to have two heads homologous to BC and COM in cats. However, the two heads in different rhesus specimens were often fused, and the number and prominence of tendinous inscriptions were found to be reduced. This trend is exaggerated in man by the more complete fusion into a single semispinalis muscle. RH cap, absent in man (Kamibayashi and Richmond 1998) was found to be present in rhesus as in the cat (Reighard and Jennings 1963).

Compared with the dorsal extensors, the suboccipital muscles were less “cat-like” and more humanoid. The close anatomical resemblance between simian and human suboccipital muscles might be viewed as evidence that suboccipital muscles in the two species are used functionally for similar purposes. One such purpose is likely to be the execution of small head movements during which they are more likely to be active than larger extensors (Corneil et al. 2001). Rhesus and human eyes

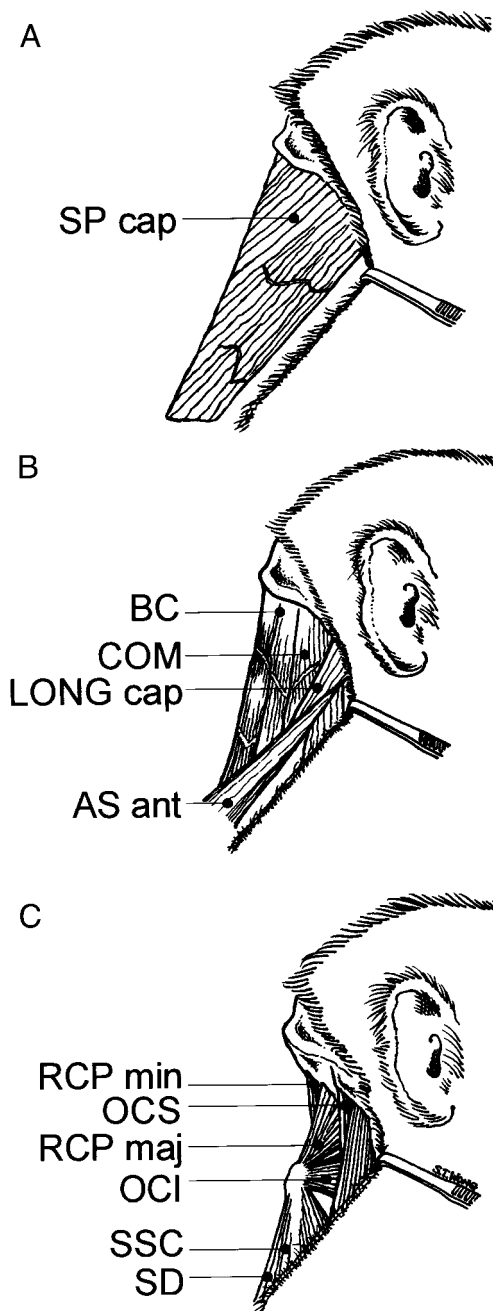


FIG. 7. Schematic drawings of dorsal neck muscles spanning between the skull and vertebral column in layers from A (superficial) to C (deep). A: splenius capitis (SP cap)—note the lateral direction of muscle fibers and partial inscriptions across the lateral part of the muscle. B: biventer cervicis (BC) and complexus (COM) are located medially and are crossed by inscriptions. Longissimus capitis (Long cap) and atlantoscapularis anterior (AS ant) run alongside the lateral aspect of the vertebral column. See also photograph in Fig. 6C. C: intervertebral and suboccipital muscles with attachments to C₁ and C₂. Abbreviations as in Table 1.

are organized similarly in the skull and are thought to move in similar ways, so that functional correlates might be expected in the muscles subserving these tasks. However, human suboccipital muscles have significantly smaller CSAs than might be expected from scaled-up rhesus values. For example, CSAs for human RCP maj and min together are only ~1.5 times those in monkeys, despite the fact that the human head is nearly 10 times larger than that of the monkey (Fig. 9). The observations

may suggest that less extensor force is needed to control sagittal-plane head movements in man; this change in requirements might affect the timing and patterns of suboccipital muscle recruitment. The larger size of rhesus suboccipital muscles may also suggest that the muscles have additional roles, such as assisting head extension when the animal adopts a quadrupedal posture. Such behaviors may not be used so commonly in humans who bear the weight of the skull in compression on a vertically oriented vertebral column during most of their waking hours.

Rearrangement of shoulder muscles

Rhesus TRAP and SCM, like rhesus suboccipital muscles, had anatomical features similar to those described in man (Kamibayashi and Richmond 1998) and other nonhuman primates (Kang 1975; Larson et al. 1991) even though the different species varied in their habitual patterns of locomotion, brachiation and prehension (Oxnard 1967). For example, rhesus TRAP, like that in man, chimpanzee, and gorilla, was a single fused muscle sheet confined almost exclusively to the dorsal surface of the body. In comparison, feline TRAP is divided into three highly differentiated heads (Reighard and Jennings 1963; Richmond et al. 1999a). The morphological differences between rhesus and feline muscles appeared to be only one aspect of a broader range of changes between the shoulder girdles of these two species. The cat has a small floating clavicle that is functionally adaptive for cursorial locomotion by increasing the range of limb excursion and thus the length of stride (Jenkins 1974). However, it provides little space for the attachment of TRAP and SCM. In primates, the clavicle forms a relatively long fixed strut between the manubrium and the scapula. The rearrangement must change the biomechanical actions and possibly the functional roles of muscles with clavicular attachments such as SCM and TRAP. In similarly structured human muscles, muscles are active during elevation of the shoulders (e.g., Bull et al. 1985). Further, the attachment of TRAP and SCM to the ribcage permits the muscles to play a role in lifting the ribcage during forcible respiratory maneuvers (Campbell et al. 1970; Legrand et al. 1997). These roles seem to contrast with patterns observed in cats, where the homologous muscles appear to be recruited only by strong ballistic movements such as head shaking (Richmond et al. 1992).

Unlike TRAP and SCM, other rhesus muscles with shoulder-girdle attachments seemed more similar to feline homologs. For example, rhesus RH was found to have a strap-like "capitis" head of similar design and fiber composition to the occipitoscapularis muscle in cats (Richmond and Abrahams 1975). Its other RH heads, RH cerv and dorsi, had features intermediate between feline and human counterparts. For example, the CSAs of RH cerv and dorsi were found to be similar in rhesus; however, in man, RH min (equivalent to RH cerv) is much smaller than RH maj (equivalent to RH dorsi), and in cats it is much larger. Until the muscles are studied biomechanically and physiologically in more detail, it will not be clear how these differences in force-generating capabilities relate to the roles played by the muscles. We might speculate that the rostral parts of rhomboideus in monkeys are larger than in humans

TABLE 3. *Fiber-type proportions and ranges in suboccipital muscles*

Suboccipital Muscle	I Ib	Ia	I	I Ib range	Ia range	I range
RCP maj	20	26	54			
81101	20	22	58	16–25	3–35	41–82
81004	17	32	50	4–25	14–47	27–82
81027	24	25	52	5–44	17–37	35–78
RCP min	44	33	23			
81101	48	30	22	31–65	25–38	8–44
81004	41	37	24	12–57	29–40	9–51
OCI	29	26	45			
81101	36	10	54	0–52	0–31	26–100
81027	19	31	50	0–49	25–36	20–75
81004	32	38	30	17–41	33–45	22–38
OCS	35	32	33			
81101	32	31	37	30–35	26–34	36–45
81004	38	34	29	23–53	32–35	12–34
RCA maj Short	29	33	38			
81101	22	38	40	16–27	24–49	26–52
81004	35	29	36	27–51	21–49	20–52
RCA maj Long	35	28	37			
81101	17	27	56	0–41	3–43	33–71
81004	53	29	18	51–55	28–30	17–19

Boldface data represent the fiber type proportions averaged for the individual animals identified below (5 digit numbers). In each specimen, the ranges of fiber-type proportions for each muscle (3 rightmost columns) suggest the relatively high degree of nonuniformity in fiber type proportions across a single muscle cross-section.

because they help to hold the necessary flexure between the thoracic and cervical column when animals adopt a quadrupedal stance. Humans usually adopt this posture for only the first year of life. The progressive expansion in the CSA of caudal RH in rhesus and human may reflect a gradual evolution in the use of the muscle in forelimb movements such as reaching.

Confusingly, certain rhesus shoulder muscles with the clos-

est resemblance to those in cats are called by different names in the most commonly referenced text of rhesus anatomy (Hartman and Straus 1961). Atlantoscapularis anterior matches feline levator scapulae ventralis, and AT post was comparable to one part of feline levator scapulae. Nevertheless, Hartman and Straus (1961) have chosen to distinguish the slip attaching to the atlas as a separate muscle (AT post) and to consider the more caudal contiguous part of the muscle as rostral serratus anterior. This nomenclature has not been employed by all anatomists. Kato and colleagues (1984, 1993) have considered the atlantal and cervical muscle slips of this complex together as levator scapulae in correspondence with descriptions in cats. We would prefer this latter choice of names because it facilitates quantitative comparisons across species.

The functional roles of AS post (levator scapulae) and AS ant (levator scapulae ventralis) are not well understood because both attachments of the muscle are mobile. AS post in rhesus as in cat (Richmond et al. 1999a) was found to be composed primarily of fast fibers as might be expected of a muscle that aids head turning. However, it may also rotate the scapula cranially (Hartman and Straus 1961). AS ant has higher proportions of slow fibers than AS post. A potential postural role may be suggested by the geometry of the muscle; its laterally directed course from the base of the skull give it the appearance of a guy wire that could be used to stabilize the head from falling to one side. Crisco and Panjabi (1990) have recently discussed the possible advantages of using superficial muscles as tethers with a long moment arms to maintain stability of a body part that is configured like an inverted pendulum, such as the neck.

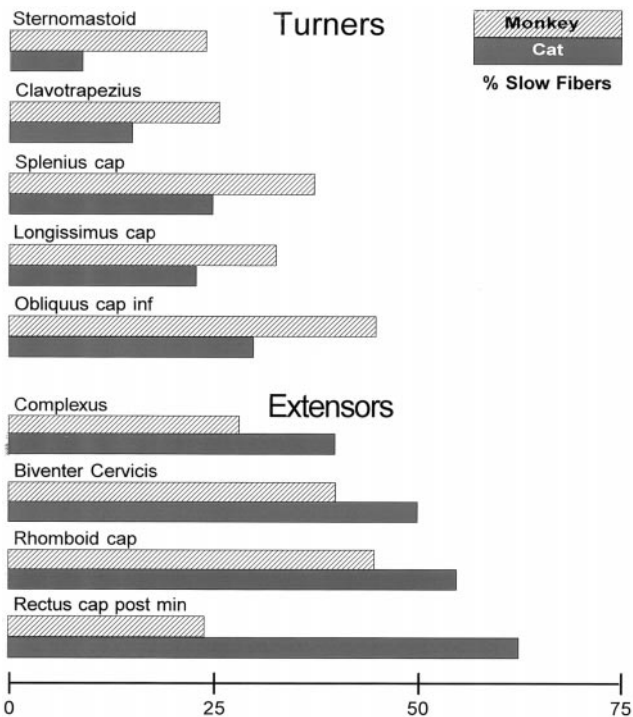


FIG. 8. Comparison of fiber-type content, given as the percentage of slow fibers in a given muscle, of monkey (▨) and feline (■) neck muscles. The muscles are grouped according to whether they function mainly as turners or extensors. Data for feline muscles taken from Richmond and colleagues (1988, 1999a) and Selbie and colleagues (1993).

Fiber-type distributions

The skeletal muscles of rhesus monkeys do not appear to differ from human or cat muscles in the types of extrafusil fibers that they contain at least when the ATPase reactivity after alkaline pretreatment is used as the criterion. Further, the

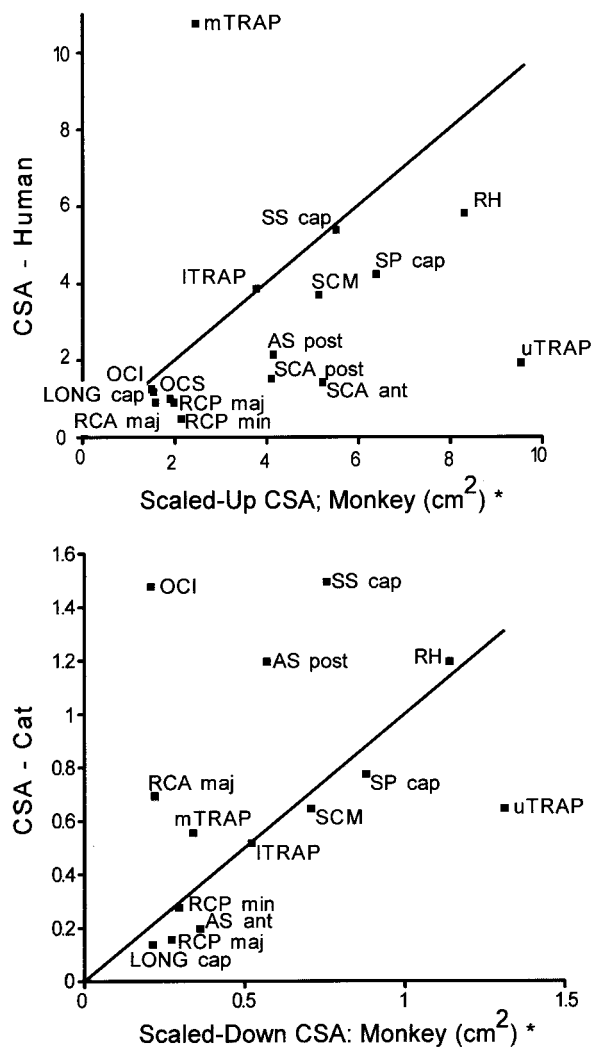


FIG. 9. Scaling differences in muscle CSA between monkeys and humans (*top*) and between monkeys and cats (*bottom*). Note that monkey neck muscles are typically larger in scaled CSA that comparable human muscles. Their scaled CSAs are more similar to those described previously in cats. * Details of how the scaled CSA values for monkey neck muscles were calculated are given in the METHODS, based on the comparison of an 8-kg monkey to a 64-kg human, or a 3.35-kg cat. [Feline data from Richmond and colleagues (1988, 1999a) and Selbie and colleagues (1993); human data from Kamibayashi and Richmond (1998).]

general features of the fiber types were typical of descriptions in other muscles and other species. For example, slow (type I) fibers were found to be most common in the centers of muscle fascicles and in the deep or core regions of some muscles. However, one aspect of fiber-type distribution in rhesus monkeys did appear to be unusual. Adjacent fiber fascicles often contained surprisingly different fiber-type proportions and occasional fascicles of fibers were found to be composed exclusively of type I fibers in regions of muscle that were otherwise typified by fascicles containing a mix of fiber types. The explanation for these fascicles is not clear. The loss of a fiber mosaic in a mixed muscle is most commonly considered to reflect a previous denervation-reinnervation process where a single motor unit “takes over” a grouping of motor units whose axons are lost (Swash and Schwartz 1998). However, the loss of mosaic is typically seen over a relatively wide field of fascicles not a single fascicle whose fibers show no other sign

of damage, such as centrally placed nuclei or connective-tissue fibrosis.

Considerations for biomechanical models

The quantitative analysis presented here was motivated in part by a need for data appropriate to model neck muscles biomechanically. The CSAs calculated for neck muscles provide some insight into muscle capabilities. Nevertheless the actions of a muscle can only be understood fully if we can evaluate its capacity to produce torque across the joint or set of joints to be moved. Because the lengths and orientations of the muscle attachments differ from one species to another, the pulling directions and moment arms of different muscles relative to different joint-sets may change as well. To gain insight into these relationships, biomechanical models will be needed to quantify muscle moments at different joints. Realistic graphical models of the human neck are now available (Vasavada et al. 1998), and similar models for cats (Statler et al. 1994) and monkeys (M. Choi and B. Peterson, unpublished data) are being developed using data such as that presented here. When the biomechanical attributes and identified activity patterns of muscles (e.g., Corneil et al. 2001) are eventually combined with the morphometric information reported here, it will be easier to compare the muscles and motor control systems in species commonly used as laboratory proxies for the human head-neck system.

Many of the muscles described here will pose significant modeling challenges. For example, SCM is a complex muscle whose fiber lengths and fascicular attachments vary. The complex organization of its multiple heads ensures that most of its force is directed laterally onto the mastoid process. Thus it would be inappropriate to model the muscle as if its line of pull was directed onto the midpoint of the occipital attachment as might be suspected from simply considering its width. In TRAP, changing fiber-type proportions and multiple attachments onto thoracic vertebrae strongly suggest a nonuniform action in different muscle parts. The cervical part of human TRAP like monkey TRAP is richer in fast fibers and is more suited to phasic activities whereas caudal parts are richer in slow fibers and may be more important for repetitive or postural roles. Thus muscles may have to be divided into subvolumes for modeling purposes as suggested for comparable human muscles (Johnson et al. 1996; Van der Helm and Veebaas 1991). A combination of morphometry and EMG analysis will be important to guide these decisions.

The results presented here were intended to provide an archival base of data that could be used as a foundation for biomechanical modeling and for electromyographic examinations of monkey neck muscles such as those that follow. In the past, studies of primate muscles have often focused on only a few easily accessible muscles, and this has led to an unrealistic assessment of the “divisions of labor” between different muscle groups. By combining the morphometric and histochemical data with a knowledge of biomechanical features and EMG activities, it may be possible to recognize evolving trends in the reorganization of the head-neck system. This may be important clinically because neck muscles often seem to be vulnerable to damage in ways that may be related to the rapid evolution of musculoskeletal relationships in the vertebral column and shoulder of bipeds.

We thank J. Creasy for excellent technical assistance and E. Cheng and E. Chung for help in collecting portions of the data. We thank E. Au-Yeung, M. Scythes, and S. Wong for excellent illustrations. We also gratefully acknowledge the aid of Dr. D. Van Vugt in obtaining some of the experimental animals.

This work was supported by a group grant from the Medical Research Council (MRC) of Canada. K. Singh was supported by a doctoral award from the MRC. B. D. Corneil was supported by an Ontario Graduate Scholarship and a doctoral award from the MRC.

REFERENCES

- BAGNALL KM, FORD DM, MCFADDEN KD, GREENHILL BJ, AND RASO VJ. A comparison of vertebral muscle fiber characteristics between human and monkey tissue. *Acta Anat* 117: 51–57, 1983.
- BERRINGER OM JR, BROWNING FM, AND SCHROEDER CR. *An Atlas and Dissection Manual of Rhesus Monkey Anatomy*. Tallahassee, FL: Anatomy Laboratory Aids, 1968.
- BULL ML, VITTI M, AND DE FREITAS V. Electromyographic study of the trapezius (upper portion) and levator scapulae muscles in some movements of the shoulders. *Anat Anz* 159: 21–27, 1985.
- CAMPBELL EJM, AGOSTONI E, AND DAVIS JN. *The Respiratory Muscles: Mechanics and Neural Control*. Philadelphia, PA: Saunders, 1970.
- CORNEIL BD, OLIVIER E, RICHMOND FJR, LOEB GE, AND MUNOZ DP. Neck muscles in the rhesus monkey. II. Electromyographic patterns of activation underlying postures and movements. *J Neurophysiol* 86: 1729–1749, 2001.
- CRISCO JJ AND PANJABI MM. Postural biomechanical stability and gross muscular architecture in the spine. In: *Multiple Muscle Systems*, edited by Winters JM and Woo SL-Y. New York: Springer-Verlag, 1990, p. 438–450.
- CULLEN KE AND GUITTON D. Analysis of primate IBN spike trains using system identification techniques. II. Relationship to gaze, eye, and head movement dynamics during head-free gaze shifts. *J Neurophysiol* 78: 3283–3306, 1997.
- FREEDMAN EG AND SPARKS DL. Eye-head coordination during head-unrestrained gaze shifts in rhesus monkeys. *J Neurophysiol* 77: 2328–2348, 1997.
- GRAF W, DE WAELE C, AND VIDAL PP. Biomechanics, movement strategies and the evolution of the head-neck system in mammals. In: *Information Processing Underlying Gaze Control*, edited by Delgado-Garcia JM, Godaux E, and Vidal PP. Amsterdam: Elsevier, 1994, p. 415–427.
- GRAF W, DE WAELE C, AND VIDAL PP. Functional anatomy of the head-neck movement system of quadrupedal and bipedal mammals. *J Anat* 186: 55–74, 1995a.
- GRAF W, DE WAELE C, VIDAL PP, WANG DH, AND EVINGER C. The orientation of the cervical vertebral column in unrestrained awake animals. II. Movement strategies. *Brain Behav Evol* 45: 209–231, 1995b.
- GUTH L AND SAMAHA FJ. Procedures for the histochemical demonstration of actomyosin ATPase. *Exp Neurol* 28: 581–598, 1970.
- HARTMAN CG AND STRAUS WL JR. *The Anatomy of the Rhesus Monkey*. New York: Hafner, 1961.
- HERZOG W, KAMAL S, AND CLARKE HD. Myofibril lengths of cat skeletal muscle: theoretical considerations and functional implications. *J Biomech* 25: 945–948, 1992.
- HSIAO CH. The deep lateral muscles of the neck in macaca cyclopis (Mm. Scalenii). *Okajimas Folia Anat Jpn* 52: 233–247, 1976.
- JENKINS FA JR. The movement of the shoulder in clavicate and aclavicate mammals. *J Morphol* 144: 71–84, 1974.
- JOHNSON GR, SPALDING D, NOWITZKE A, AND BOGDUK N. Modelling the muscles of the scapula morphometric and coordinate data and functional implications. *J Biomech* 29: 1039–1051, 1996.
- JUSCHKE S. Untersuchungen zur funktionellen Anpassung der Rückenmuskulatur und der Wirbelsäule quadrupeder Affen und Kanguruhs. *Z Anat Entwicklungsgesch* 137: 47–85, 1972.
- KAMBAYASHI LK AND RICHMOND FJR. Morphometry of human neck muscles. *Spine* 23: 1314–1323, 1998.
- KANG WB. The superficial lateral muscles of the neck in macaca cyclopis (formosan monkey). *Okajimas Folia Anat Jpn* 52: 151–165, 1975.
- KATO K AND HOPWOOD P. Innervation of the levator scapulae, the serratus anterior, the rhomboideus and the scapular muscles in the gray kangaroo (macropus giganteus). Comparisons are drawn to the crab-eating macaque and man. *Anat Anz* 175: 21–28, 1993.
- KATO K AND SATO T. Innervation of the levator scapulae, the serratus anterior, and the rhomboideus in crab-eating macaques and its morphological significance. *Anat Anz* 157: 43–55, 1984.
- LARSON SG, STERN JT, AND JUNGENS WL. EMG of serratus anterior and trapezius in the chimpanzee: scapular rotators revisited. *Amer J Phys Anthropol* 85: 71–84, 1991.
- LE GROS CLARK WE. *The Antecedents of Man: An Introduction to the Evolution of the Primates*. Edinburgh, UK: Edinburgh University, 1962, p. 124–226.
- LEGRAND A, NINANE V, AND DE TROYER A. Mechanical advantage of sternomastoid and scalene muscles in dogs. *J Appl Physiol* 82: 1517–1522, 1997.
- MACPHERSON JM AND YE Y. The cat vertebral column: stance configuration and range of motion. *Exp Brain Res* 119: 324–332, 1998.
- MCINTOSH JS, RINGQVIST M, AND SCHMIDT EM. Fiber type composition of monkey forearm muscle. *Anat Rec* 211: 403–409, 1985.
- MENDEZ J AND KEYS A. Density and composition of mammalian muscle. *Metabolism* 9: 184–188, 1960.
- MOSCHOVAKIS AK, SCUDDER CA, AND HIGHSTEIN SM. The microscopic anatomy and physiology of the mammalian saccadic system. *Prog Neurobiol* 50: 133–254, 1996.
- NAPIER JR AND NAPIER PH. *The Natural History of the Primates*. Cambridge, MA: MIT Press, 1985.
- OXNARD CE. The functional morphology of the primate shoulder as revealed by comparative anatomical, osteological and discriminant function technique. *Am J Phys Anthropol* 26: 219–240, 1967.
- REIGHARD J AND JENNINGS HS. *Anatomy of the Cat*. New York: Holt Rinehard and Winston, 1963.
- RICHMOND FJR AND ABRAHAMS VC. Morphology and enzyme histochemistry of dorsal muscles of the cat neck. *J Neurophysiol* 38: 1313–1321, 1975.
- RICHMOND FJR, LIINAMAA TL, AND KEANE J. Morphometry, histochemistry, and innervation of cervical shoulder muscles in the cat. *J Morphol* 239: 255–269, 1999a.
- RICHMOND FJR, MACGILLIS DRR, AND SCOTT DA. Muscle-fiber compartmentalization in cat splenius muscles. *J Neurophysiol* 53: 868–885, 1985.
- RICHMOND FJR, SINGH K, AND CORNEIL BD. Marked non-uniformity of fiber-type composition in the primate suboccipital muscle obliquus capitis inferior. *Exp Brain Res* 125: 14–18, 1999b.
- RICHMOND FJR, THOMSON DB, AND LOEB GE. Electromyographic studies of neck muscles in the intact cat. I. Patterns of recruitment underlying posture and movement during natural behaviors. *Exp Brain Res* 88: 41–58, 1992.
- RICHMOND FJR AND VIDAL PP. The motor system: joints and muscles of the neck. In: *Control of Head Movement*, edited by Peterson BW and Richmond FJR. New York: Oxford, 1988, p. 1–21.
- RUNCIMAN RJ AND RICHMOND FJR. Shoulder and forelimb orientations and loading in sitting cats: implications for head and shoulder movement. *J Biomech* 30: 911–919, 1997.
- SCHMIDT-NIELSEN K. *Scaling: Why is Animal Size so Important?* Cambridge, UK: Cambridge Univ Press, 1984.
- SELBIE WS, THOMSON DB, AND RICHMOND FJR. Suboccipital muscles in the cat neck: morphometry and histochemistry of the rectus capitis muscle complex. *J Morphol* 216: 47–63, 1993.
- STATLER KD, KESHNER EA, DELP SL, AND PETERSON BW. Application of a computer graphics based model to cat head-neck kinematic data. *Soc Neurosci Abstr* 20: 795, 1994.
- SWASH M AND SCHWARTZ MS. *Neuromuscular Diseases*. London: Springer-Verlag, 1988, p. 75–77.
- SZEBENYI ES. *Atlas of Macaca Mulatta*. Cranbury, NJ: Associated University Press, 1969.
- TOBIAS PV. The upright head in hominid evolution. In: *The Head-Neck Sensory Motor System*, edited by Berthoz A, Graf W, and Vidal PP. New York: Oxford, 1992, p. 5–13.
- VAN DER HELM FC AND VEEBAAS R. Modelling the mechanical effect of muscles with large attachment sites: application to the shoulder mechanism. *J Biomech* 24: 1151–1163, 1991.
- VASAVADA AN, LI S, AND DELP SL. Influence of muscle morphometry and moment arms on the moment-generating capacity of human neck muscles. *Spine* 23: 412–422, 1998.
- VIDAL PP, GRAF W, AND BERTHOZ A. The orientation of the cervical vertebral column in unrestrained awake animals. I. Resting position. *Exp Brain Res* 61: 549–559, 1986.